



NATIONAL
BREAST AND OVARIAN
CANCER CENTRE

The pathology reporting of breast cancer

A guide for pathologists, surgeons,
radiologists and oncologists



The pathology reporting of breast cancer

A guide for pathologists, surgeons,
radiologists and oncologists

National Breast and Ovarian Cancer Centre
and
Australian Cancer Network

3rd edition

The pathology reporting of breast cancer. A guide for pathologists, surgeons, radiologists and oncologists (3rd edition) was prepared and produced by National Breast and Ovarian Cancer Centre and Australian Cancer Network.

National Breast and Ovarian Cancer Centre (NBOCC)

Suite 103/355 Crown Street Surry Hills NSW 2010

Locked Bag 3 Strawberry Hills NSW 2012 Australia

Telephone: +61 2 9357 9400 Fax: +61 2 9357 9477

Website: www.nbocc.org.au

Email: director@nbocc.org.au

ISBN Print: 978-1-74127-077-8 Online: 978-1-74127-088-4 CIP: 11543

© National Breast and Ovarian Cancer Centre 2008

This work is copyright. Apart from any use as permitted under the Copyright Act 1968, no part might be reproduced by any process without prior written permission from the National Breast and Ovarian Cancer Centre. Requests and enquiries concerning reproduction and rights should be addressed to the Public Affairs Manager, National Breast and Ovarian Cancer Centre, director@nbocc.org.au

Recommended citation

National Breast and Ovarian Cancer Centre and Australian Cancer Network. *The pathology reporting of breast cancer. A guide for pathologists, surgeons, radiologists and oncologists (3rd edition)*. National Breast and Ovarian Cancer Centre, Surry Hills, NSW, 2008.

Disclaimer

National Breast and Ovarian Cancer Centre does not accept any liability for any injury, loss or damage incurred by use of or reliance on the information. National Breast and Ovarian Cancer Centre develops material based on the best available evidence, however it cannot guarantee and assumes no legal liability or responsibility for the currency or completeness of the information.

Copies of this report can be downloaded from the National Breast and Ovarian Cancer Centre website: www.nbocc.org.au or ordered by telephone: 1800 624 973

National Breast and Ovarian Cancer Centre is funded by the Australian Government Department of Health and Ageing.

Endorsed by:



Contents

Acknowledgements	5
Foreword	6
Introduction	8
Pathology – a core component of multidisciplinary care	8
1. The pathology request form	10
2. Surgical handling of specimens	12
Sutures	12
Clips	12
3. Specimen imaging	13
Specimen orientation	13
Specimen radiography	13
Imaging of sliced specimens and paraffin blocks	14
Radiographic technique	14
Ultrasonography	14
4. Handling and macroscopic examination of breast specimens	15
Intra-operative consultations	15
Diagnostic open biopsy	15
Wide local excision (partial mastectomy, segmentectomy)	16
Re-excision specimens	17
Mastectomy specimens	18
Core biopsy	19
Tissue banking	19
Examination of lymph nodes for metastasis	19
5. Microscopic reporting of invasive carcinoma	22
Synoptic report	22
Diagnostic summary	22
Site	22
Tumour type	22
Invasive carcinoma size and lesion size	22
Histological grade of invasive carcinoma	26
Lymphovascular invasion	29
DCIS in specimen	29
Resection margins	29
Atypical lobular hyperplasia/lobular carcinoma in situ	29
Paget's disease of the nipple	29
Microcalcification	30

Benign and proliferative changes	30
Oestrogen receptor, progesterone receptor and HER2 assays	30
6. Microscopic reporting of ductal carcinoma in situ	31
Size	31
Margins	31
Nuclear grade	31
Necrosis	32
Van Nuys Prognostic Index	32
Architecture	33
Microcalcification	33
Synoptic report	33
7. Hormone receptor assays and other prognostic and predictive factors	35
Hormone receptor assays	35
HER2 assays	37
Other markers	43
Appendix–Lobular neoplasia	45

Acknowledgements

National Breast and Ovarian Cancer Centre and The Australian Cancer Network gratefully acknowledge the support of all the individuals and groups who contributed to the development of this guide.

Funding

Funding for the development of this guide was provided by the Australian Government Department of Health and Ageing.

The Australian Cancer Network contributed to the administrative costs of the Working Group.

Working Group

Associate Professor Michael Bilous (Joint Chair), Pathologist

Emeritus Professor Tom Reeve (Joint Chair), Senior Medical Advisor, Australian Cancer Network

Professor Bruce Barraclough, Director, Australian Cancer Network

Dr Gelareh Farshid, Pathologist, Royal College of Pathologists of Australasia representative

Dr James French, Surgeon, Royal Australasian College of Surgeons representative

Ms Helen Farrugia, Director of Information Systems, Victorian Cancer Registry

Associate Professor David Gillett, Surgeon, Royal Australasian College of Surgeons representative

Associate Professor Michael Green, Medical Oncologist Medical Oncology Group of Australia representative

Associate Professor Jennet Harvey, Pathologist

Associate Professor Michael Henderson, Surgeon

Dr Liz Kenny, Radiation Oncologist, The Royal Australian and New Zealand College of Radiologists representative

Dr Marjorie Kossoff, Radiologist

Professor Sunil Lakhani, Pathologist

Mr David Oliver, Surgeon, Royal Australasian College of Surgeons representative

Dr Wendy Raymond, Pathologist, Royal College of Pathologists of Australasia representative

Professor Greg Sterrett, Pathologist, Royal College of Pathologists of Australasia representative

Dr Helen Zorbas, Breast Physician, Director, National Breast and Ovarian Cancer Centre

Secretariat

Ms Holly Goodwin, National Breast and Ovarian Cancer Centre

Ms Caroline Nehill, National Breast and Ovarian Cancer Centre

Ms Christine Vuletich, Australian Cancer Network

Medical Writer

Ms Jenni Harman, Meducation

Foreword

National Breast and Ovarian Cancer Centre (NBOCC) and The Australian Cancer Network (ACN) have worked in partnership to develop this edition of *The pathology reporting of breast cancer*, first published in 1997 and revised in 2000.

This document reflects current evidence and best practice, but the field of pathology reporting in breast cancer is changing from day to day in response to advances in tailored breast cancer management. Updates in response to any significant change in the evidence will be posted on the NBOCC website.

The pathologist provides the vital information central to the deliberations of the multidisciplinary treatment team. Consistency of reporting and recording of key pathology features support the implementation of best practice treatment.

Synoptic reporting in pathology helps to ensure better communication between clinicians, with less likelihood of misinterpretation of findings. The Royal College of Pathologists of Australasia supports the use of synoptic reports as a desirable standard for reporting of definitive resection specimens for major tumour types.

As the biology of breast cancer is becoming better understood, and as new treatments emerge, the management of breast cancer is increasingly being tailored according to patient and tumour factors. Providing an accurate understanding of the distinct pathology features of an individual patient's breast cancer enables treatment protocols to be tailored to tumour characteristics based on the latest evidence.

NBOCC and the ACN acknowledge with gratitude the contributions of the multidisciplinary working group established to develop this guide. The recommendations are based on best available evidence where it exists, or on expert consensus opinion where there is a paucity of published data. The joint chairmanship of Emeritus Professor Tom Reeve and Associate Professor Michael Bilous provided a seamless evolution from the previous editions and resulted in another high quality document.

Professor Bruce Barraclough AO
Director, Australian Cancer Network

Dr Helen Zorbas
Director, National Breast and Ovarian Cancer Centre

A foreword from joint Chairs of the working party

In approaching the third revision of *The pathology reporting of breast cancer – a guide for pathologists, surgeons, radiologists and oncologists*, the ACN and NBOCC have pooled their resources. Both institutions have been gratified by the interest shown in this guideline and by increasing implementation since its inception. The document has been materially enhanced by feedback from the specialists for whom it has been developed, together with wider changes in practice. The current revision has again involved a body of people who are committed to cancer control and the promotion of the best possible practice to achieve it.

NBOCC has been a leader in promoting multidisciplinary care, and it is clear that the best level of pathology practice and reporting is essential in achieving this type of care for patients with breast cancer. Furthermore, the move towards synoptic reporting should lead to greater consistency in patient care, as the pathological findings form an imperative part of the multidisciplinary team's considerations. Care taken in recording data is crucial to ensure accuracy of the final report, and this depends on the commitment of the clinicians involved.

Guidelines like this involve a wide range of specialists and the colleges they represent, and result from the enormous goodwill that prevails in Australian medicine. Both the ACN and NBOCC express their gratitude for the assistance, support and good humour that has prevailed throughout the development process. We are indebted to Ms Jenni Harman for her careful editing and to staff from both organisations for their devotion to typing and formatting drafts.

We thank the Medical Director of ACN, Professor Bruce Barraclough AO, and the Director of NBOCC, Dr Helen Zorbas, for their unremitting support of all involved in the development of the document.

Joint Chairs of the working party

Emeritus Professor Tom Reeve AC CBE
Senior Medical Advisor
Australian Cancer Network

Associate Professor Michael Bilous
Head of Department of Tissue Pathology,
Institute of Clinical Pathology and Medical
Research, Westmead Hospital

Introduction

Pathology – a core component of multidisciplinary care

The pathologist's contribution is an essential component of multidisciplinary care. The multidisciplinary approach to health care involves medical and allied health professionals collaborating as an integrated team to develop an individualised treatment plan for each patient, by reviewing clinical and personal circumstances and considering all relevant treatment options. Access to a clear and comprehensive pathology report, which details all relevant information about the patient's tumour, is critical to the team's ability to determine appropriate treatment.

Multidisciplinary care is an increasingly important component of national and state/territory cancer frameworks. Australia's mix of private and public health services, and our significant regional variations in service delivery and access, present a challenge for the implementation of multidisciplinary care. The principles of multidisciplinary care developed by National Breast Cancer Centre* (NBCC)^{1,2} are based on a definition of multidisciplinary care that is flexible and recognises that implementation will vary between different locations. The principles emphasise the need for:

- **a team approach** involving core disciplines integral to the provision of good care
- **communication** among team members regarding treatment planning
- **access** to the full range of therapies for all patients, regardless of geographical remoteness or size of institution
- **nationally agreed standards** of care
- **involvement of patients** in decisions about their care.

A thorough consideration of the pathology findings is essential to enable clinicians to make fully informed decisions about each patient's treatment. Correlation of the pre-operative clinical findings with those of imaging, percutaneous biopsy and surgical histopathology is a vital part of the multidisciplinary assessment process and is fundamental to good patient management.

It is important that clinicians treating patients with breast cancer develop a good working relationship with pathologists experienced in breast pathology. While the pathology report should contain all of the essential information required for clinical management, discussion with the pathologist often provides further information about individual cases. The multidisciplinary meeting provides the opportunity for pathologists to present an individual's results and to discuss findings with other treatment team members, and for clinicians to view slides or images with the pathologist. This kind of communication is particularly valuable if there is any information in the pathology report that is complex or unexpected.

**In February 2008, National Breast Cancer Centre (NBCC) changed its name to National Breast and Ovarian Cancer Centre (NBOCC).*

Since each discipline contributes a specialised knowledge and perspective, multidisciplinary professional interaction is a very productive exercise. All multidisciplinary team members should work to establish and maintain good communication links with other team members involved in the care of patients with breast cancer. Effective communication can be achieved through face-to-face meetings, teleconferences and videoconferences. The non-medical staff should be encouraged to develop an understanding of how the pathology findings affect the clinical course of the malignancy.

The synoptic report arranges pathology information in a logical way that acts as a checklist for pathologists and provides managing clinicians with ready access to the most important pathology information. This report format also simplifies the processes of auditing and entering data to cancer registries. The synoptic report does not necessarily replace the descriptive report, but each may complement the other. Not all pathology information can be expressed in discrete variables or on a numerical scale. A prose description may be required to supplement the synoptic report in the case of complex findings or to express biological variation.

A better understanding of the perspectives of other disciplines will improve cooperation with formal systems for collecting and passing on information. Just as the pathology report is designed to provide clinicians with information on which to base management decisions, the pathology request form sets out the information essential for the pathologist to extract the most clinically relevant information from a specimen.

Appropriately developed request and reporting systems – tailored to the needs and clinical practices of the entire multidisciplinary team – benefit all involved clinical and allied health professionals, and promote optimal outcomes for patients.

References

1. National Breast Cancer Centre. Multidisciplinary care in Australia: a national demonstration in breast cancer. Camperdown, NSW: National Breast Cancer Centre, 2003.
2. National Breast Cancer Centre. Multidisciplinary meetings for cancer care: a guide for health service providers. Camperdown, NSW: National Breast Cancer Centre, 2006.

1. The pathology request form

The use of a standardised request form for all breast tissue specimens is strongly recommended (Figure 1). Clinical staff should be aware that each piece of information requested in the sample form is necessary for pathologists to perform an examination properly.

All requests for pathology of a specimen of breast tissue should include a minimal dataset, to ensure consistency and the long-term integrity of the pathology report. The information should be precise and provided by the surgeon or other clinician as relevant to the specimen type.

The pathology request should include at least the following items of information:

- Date and time of surgery
- Number of specimen containers submitted
- History and clinical findings including: right or left breast, number of lesions, and the size, location within the breast (clock-face position) and distance from nipple for each lesion
- Imaging results including type of imaging abnormality, final imaging classification, location of imaging abnormality (clock-face position) and distance from nipple
- Biopsy results for each lesion using standard codes. The lesion number should correlate with the clinical findings section, the imaging section, or both.
- A diagram indicating the location of incisions and position of orientating sutures or clips. This helps the pathologist to orientate the specimen accurately.
- Method of localisation used
- Whether the relevant lesion was identified on specimen imaging (mammographic or ultrasound), if performed. For radiographs, a duplicate image (and radiology report, if available) should be forwarded to the pathology department. Radioactive specimens should be clearly labelled.
- For sentinel lymph nodes: location and radioactivity count
- For axillary specimens: a clear indication of level from which retrieved.

Each specimen container should be clearly labelled with the name of the patient and the nature, site and side of the specimen. If the specimen is radioactive, this should be clearly indicated on the label.

Note: Pathology request forms are valid for reimbursement purposes only if they have been pre-approved by Medicare Australia.

Figure 1. Sample pathology request form

<NAME OF INSTITUTION>

Breast histopathology request form

Patient details

Last Name First Name

Street Suburb Postcode

Sex Date of birth Medical record no. Ward

Phone Managing consultant

Patient status at time of collection

Private patient in a private hospital or approved day hospital facility

An outpatient of a recognised hospital

A Medicare (public) patient in a recognised hospital

A private patient in a recognised hospital

Medicare Assignment

To be completed by the person offering to assign benefits for the services on this form. (Section 20A of the Health Insurance Act 1973). I offer to assign my right to benefits to the Approved Pathology Practitioner who will render the requested pathology services.

Medicare/Repat no.

X Patient signature Date

PRIVACY NOTE: The information provided will be used to assess any Medicare benefit payable for the services rendered and to facilitate the proper administration of government health programs, and may be used to update enrolment records. Its collection is authorised by provision of the Health Insurance Act 1973. The information may be disclosed to the Department of Health and Ageing or to a person in the medical practice associated with this claim, or as authorised/required by law.

Practitioner's use only

(Reason person unable to sign)

History and clinical findings

Include side, o'clock position, type of lesion (e.g. calcification), distance from nipple

Imaging results

Pre-op pathology results

1 = non-diag 2 = benign 3 = atypical 4 = suspicious 5 = malignant

	Lesion 1	Lesion 2	Lesion 3
FNA			
Core biopsy			
Open biopsy			

Breast specimen site

Sutures

Long = lateral Medium = medial

Deep margin pectoral fascia

Short = superior Loop = cavity side

Comments

Breast specimen type

Excision biopsy SIDE R L Mastectomy SIDE R L

Wide local excision R L Re-excision R L

Localisation

Yes No

Localisation method Carbon Hookwire

Specimen imaging done

Yes No

Lesion seen on specimen imaging? Yes No

Sentinel lymph node biopsy performed

Yes No

No.	Site	Count	Blue (Yes/No)
1			
2			
3			
4			

Sites: Axilla levels I, II, III, IMC (state interspace), other

Axillary specimen

Yes No

Level I Non-sentinel nodes Sample Level II Level III

Requesting Doctor

Tick if self determined

Surname and initials Address

Provider number Phone Fax

Copy report to: (surname, initial, street, suburb)

Doctor's signature **X** Date of surgery

Adapted from The Institute of Clinical Pathology and Medical Research, Western Sydney Area Health Service

2. Surgical handling of specimens

The surgical specimen should be orientated and marked by the surgeon using clips and/or sutures, following an agreed local protocol. The placement of markers and the protocol used must be identified on the request form (Figure 1).

Three separate markers are usually necessary for accurate orientation, as well as an indication of whether the specimen is from the left or right breast. Suitable markers include sutures of varying lengths and varying numbers of clips. Clips offer the advantage of radio-opacity. Standard protocols include the following examples.

Sutures

Short suture = superior aspect of specimen

Medium suture = medial aspect of specimen

Long suture = lateral aspect of specimen

For small cavity shave re-excisions, it may be adequate to place a single suture on the cavity side. For larger re-excision specimens, the specimen should be orientated in three dimensions by placing a single suture on the superficial aspect and a knotted or double suture deep, both on the cavity side. It is also helpful to provide a diagram showing the relationship between specimens.

Clips

1 clip = superior aspect of specimen

2 clips = medial aspect of specimen

3 clips = lateral aspect of specimen

Total mastectomy specimens without attached axillary contents should be orientated by the use of a single clip or suture at the '12 o'clock' position or other agreed reference point as noted on the request form.

The use of diathermy should be avoided because it may cause cautery artefact, which may compromise interpretation of the specimen by the pathologist.

In centres with onsite pathology, specimens should immediately be placed in a plastic bag or container on ice and transported fresh, whether to the radiology department for imaging or to the pathology department for inking of margins, removal of samples for tissue banking and, if necessary, for slicing prior to fixation. In centres that use an external pathology service, or when immediate transport is not possible, the specimen should immediately be placed in formalin (at least twice the specimen volume). The container should be large enough to ensure that no distortion of the specimen occurs.

Ideally, the specimen should be dispatched to the pathologist intact. However, under circumstances in which a transport delay is likely (e.g. rural and remote areas), deep incision (but not transection) of the specimen through the tumour is recommended to enable formalin to penetrate the tissue.

3. Specimen imaging

Specimen imaging should be performed for wide local excision specimens from clinically impalpable, radiographically detected lesions to ensure that the lesion is contained in the specimen and to indicate the position of the lesion within the specimen for optimal evaluation by the pathologist. Specimen radiography for all impalpable lesions is a BreastScreen Australia National Accreditation Standard.¹ Correlation of pathology with imaging is required to ensure that the findings are congruent.

Imaging may also be considered for mastectomy specimens, particularly if the lesion is impalpable (e.g. ductal carcinoma in situ, small lesion in a large breast, or if there are multiple lesions). Depending on the requirements of the laboratory, imaging may be performed on the whole specimen or after slicing. In general, blocks should not be taken until the lesion has been localised.

Specimen orientation

Prior to specimen radiography, the specimen should be orientated in its anatomical position according to the sutures or other orientation markers placed by the surgeon. Appropriate radio-opaque markers should then be placed to indicate the position of these markers, in accordance with an agreed protocol. This allows the pathologist to reproduce the orientation of the specimen shown in the radiograph and to determine the position of impalpable lesions (see **Chapter 2. Surgical handling of specimens**).

Alternatively, the specimen may be placed in a specimen holder that incorporates a radio-opaque grid for specimen radiography, then transported to the pathology service in the holder. This enables the pathologist to determine the location of the lesion accurately by referring to the specimen radiograph.

Specimen radiography

Specimen radiography should be carried out and interpreted promptly, especially if the patient is kept anaesthetised. The radiologist reporting the specimen radiograph should ensure that the original mammograms are available for comparison.

The radiologist should contact the surgeon to report whether or not the lesion can be detected radiographically within the specimen, as well as provide a written report on all specimen radiographs.

A copy of the radiology report should accompany the film, and both should be transported with the specimen to the pathology department as quickly as possible. The radiologist should indicate on the film the position of the relevant radiographic lesion, to help the pathologist identify its position in the specimen.

Note: Disappearance of radiographically detected microcalcifications in core biopsies has been reported following formalin fixation.²

Imaging of sliced specimens and paraffin blocks

The position of the lesion in one or a number of contiguous slices can be determined by radiographic examination. This is particularly useful when the lesion is very small. If radiography of a sliced specimen is performed, an unmagnified film may be used as a key to identify the origin of blocks taken, by marking these directly on the film.

If radiography of a specimen has demonstrated that the lesion is present, but it has not been seen on microscopy by the pathologist, it may be necessary to radiograph the paraffin blocks (particularly in the case of microcalcifications).

Radiographic technique

Specimen radiography is best performed by a radiographer on a clinical mammography machine or Faxitron. Two specimen radiographs should be obtained so that one can accompany the specimen to the pathology department, and one can be kept with the mammograms. Two views may be helpful.

Magnification

In general, a specimen radiograph should be obtained by geometric magnification using a regular mammography magnification stand. This is particularly important when the mammographic abnormality is the presence of microcalcifications.

Specimen compression

Compression is generally not required and should be avoided. Prolonged compression or overcompression of a specimen can result in irreversible distortion of the tissue. This can compromise pathology assessment, particularly if the distortion involves excision margins.

Exposure

Magnification images are performed without a grid. A low kVp (eg 22–25 kVp) is necessary. The automatic exposure control device on clinical mammography machines can be used if the specimen is large enough to cover the chamber. The specimen must be centred over the automatic exposure control chamber.

The radiologist should compare the appearance of the specimen radiograph with the pre-operative mammogram to determine whether or not the lesion in question has been removed. According to established best practice, the pathologist should state in the pathology report whether a specimen radiograph accompanies the specimen, and should correlate the radiographic appearance with the histology findings. Dense stellate lesions and microcalcifications will be readily visible on specimen radiographs. Relatively low-density soft tissue lesions with ill-defined margins are often more difficult to detect.

Ultrasonography

An impalpable lesion may not be visible on mammography and may require pre-operative localisation by ultrasound. If such a lesion is not visible on the specimen radiograph, specimen ultrasonography may be required to identify the lesion and to confirm that it has been excised. The tissue may be placed inside a plastic bag or covered with cling wrap to prevent contact between the tissue and the transducer or ultrasound gel.

References

1. Australian Screening Advisory Committee. National accreditation handbook. Canberra; Commonwealth of Australia, 2005.
2. Moritz JD, Luftner-Nagel S, Westerhof JP, Oestmann JW, Grabbe E. Microcalcifications in breast core biopsy specimens: disappearance at radiography after storage in formaldehyde. *Radiology* 1996; 200: 361–363.

4. Handling and macroscopic examination of breast specimens

The following information should be included in the macroscopic section of the pathology report on a breast excision specimen:

- Type, number and laterality of specimens
- Specimen size in millimetres measured in three dimensions, and weight in grams
- Location of orientating sutures or clips
- The presence of a carbon track or hook wire
- Presence and dimensions of any associated skin
- Description of any grossly abnormal areas in three dimensions, the relationship of these to the excision margins, and the distance to the nearest margins measured.

Intra-operative consultations

Frozen section for breast specimens

Intra-operative frozen section examination of breast specimens is rarely justified, because pre-operative fine needle aspirate or core needle biopsies are now readily available. The pathologist should decline requests for frozen section in cases in which freezing the tissue is likely to compromise section quality and therefore jeopardise subsequent examination. In general, this includes all lesions measuring less than 10 mm in greatest dimension, and all impalpable lesions, such as those associated with microcalcifications.

Gross examination of wide local excision specimens for margin assessment

Surgeons may request intra-operative gross inspection of wide local excision specimens to assess adequacy of margins. This practice demands a substantial time commitment on the part of the pathologist. The request should be negotiated ahead of time between the departments involved. If gross examination of margins is required, the fresh specimens may be cooled in the freezing compartment of a refrigerator for up to 20 minutes to facilitate slicing, inked (see **Wide local excision**, below) and sliced serially at 4 mm intervals to permit careful gross examination of margins. Care should be taken to prevent the spread of marking ink, which may compromise subsequent paraffin section examination.

Diagnostic open biopsy

Open biopsy specimens may not carry orientating sutures. Nevertheless, it may be useful to ink all margins in one colour in the event that a carcinoma is detected. Weigh, measure, fix and slice as for a wide local excision specimen. Because there is no firm pre-operative diagnosis in most cases involving open biopsy, the pathologist must confirm that the intended tissue has been removed by correlating the specimen with the imaging findings or clinical indication for surgery. Care should be taken to ascertain the maximum extent of the lesion, as this may be the best opportunity to establish tumour size.

Wide local excision (partial mastectomy, segmentectomy)

Initial handling

The fresh specimen may be marked with ink and sliced immediately. Alternatively, it may first be allowed to cool in the freezing compartment of a refrigerator for up to 20 minutes or fixed in 10% buffered formalin.

1. Orientate the specimen using any skin, marking sutures and clips placed by the surgeon.
2. Weigh the specimen.
3. Measure the specimen in three dimensions. The surfaces of most importance are medial, lateral, superior and inferior. In many cases the superficial aspect of the specimen extends to the skin and the deep aspect to the pectoral muscle, such that little residual breast tissue is available for re-excision.
4. Before cutting any breast tissue specimen in the laboratory, the margins should be marked using indelible inks (India ink, Alcian Blue or other commercially available pigments). Adherence of marking solutions may be improved by drying the specimen and/or dipping it in alcohol or Carnoy's fixative. Different colours should be used to highlight different surfaces.
5. Take a series of slices 3–5 mm thick, slicing radially towards the nipple. This is recommended because ductal carcinoma in situ (DCIS) and some invasive cancers have their greatest dimension in this plane. The slices should be laid out sequentially and orientation of the specimen should be maintained.

The presence of any suspicious lesion, cavity or biopsy site should be described and measured in three dimensions. The clearance to each of the margins should be measured in the gross state, particularly when < 10 mm. DCIS with necrosis may form firm cords in the tissue, from which cream-coloured material oozes or can be expressed. The extent of any such lesions should be measured, as their presence may aid sampling.

The macroscopic report should include a written record of blocks selected, in addition to a diagram or photograph.

Sampling

Block selection depends largely on whether or not a lesion is grossly identifiable. The number of blocks necessary may be limited by taking an initial minimal set, maintaining the orientation of the cut slices by storing them securely so as to allow subsequent sampling. To avoid the need to return for additional blocks, many pathologists find it easier to embed smaller specimens (e.g. < 70 mm in maximum diameter) *in toto*.

If a grossly identifiable lesion is present, take blocks from the lesion (completely embedding small lesions). Take the most peripheral two lesion-containing slices to document the maximum extent of the tumour and the adjacent grossly uninvolved slices. The size of the lesion would be the number of slices involved multiplied by slice thickness.

Take blocks from the closest margins in each plane, including the most peripheral shaved or tangential margins, and to assess the spread of DCIS towards the nipple. Although two to three blocks of a large cancer are usually representative, extra blocks may be useful for future research

purposes. Sampling of adjacent macroscopically normal breast is helpful to confirm normal fibrous parenchyma, and increases the detection rate for occult cancers.

The pathology report should contain specific information on the orientation of each block and may be accompanied by a diagram, photograph or specimen radiograph as appropriate.

Excisions performed for impalpable lesions

The cut slices may be radiographed to detect the lesion, to direct block-taking and to enable correlation between the radiological and histological findings.

Restricting histological examination to areas of radiographic calcifications and fibrous parenchyma results in a high detection rate for clinically significant lesions and a 20% reduction in the amount of tissue processed, compared with submitting the specimen *in toto*.¹ The size of DCIS may be determined based on the maximal dimension on a slide and the sum of the number of consecutive slides containing the lesion multiplied by the slice thickness.

Grossly benign tissue

The likelihood of detecting carcinoma or atypical hyperplasia exclusively in the adipose tissue component of grossly benign breast biopsies has been shown to be extremely low.² A cost-effective sampling method in this situation involves initially submitting a maximum of 10 blocks of fibrous parenchyma for each case, then examining the remaining tissue histologically only if carcinoma or atypical hyperplasia is found in the original blocks.

Shaved versus inked margins

The use of shaved margins immediately adjacent to the tumour is not recommended, as their clinical value is limited by a low level of concordance with inked margins. Approximately 40% of specimens with positive shaved margins do not show positive inked perpendicular margins. For negative shaved margins, there is a higher concordance with inked margins.³

Re-excision specimens

Re-excision is sometimes performed to improve local control when initial surgical margins are positive. Note that residual tumour tissue is present in less than half (approximately 40%) of all specimens from re-excisions performed when initial margins were positive or indeterminate. This rate is typical for invasive carcinoma, but varies according to the initial pathology.

The surgeon should orientate the specimen with a suture on the prior cavity site (**see Chapter 2. Surgical handling of specimens**). The original and new margins may be inked in different colours. The specimen is sliced serially along the longest axis. The specimen may be submitted either entire, or as two blocks per 10 mm (suitable for grossly benign re-excisions).⁴

Mastectomy specimens

Orientate, measure and weigh the specimen and ink the margins (using contrasting colours for the deep, superior and inferior surfaces, if preferred). Slice sagittally at 10 mm intervals, leaving the skin intact, thus 'bread-loafing' the specimen to facilitate fixation. Paper towelling may be placed between the slices to ensure penetration of the formalin and to facilitate fixation. Allow the specimen to fix completely.

1. Describe the skin and nipple and comment on the presence of skin oedema (peau d'orange), Paget's disease of the nipple, skin ulceration and any skin nodules. Describe and measure accompanying tissues such as the axillary tail, skeletal muscle or chest wall.
2. Record the size of any tumour in three dimensions and its distance from margins, the skin, muscle, fascia or nipple. Record the location of each tumour with respect to the conventionally recognised quadrants (upper inner, lower inner, upper outer and lower outer) and/or clock face, including the distance of each lesion from the nipple, depth beneath the skin and from other margins, and distance from other masses.
3. Take a disc of nipple and serially section in transverse sections. A coronal section from the base of the nipple may also be sampled.
4. Take representative blocks of each tumour and adjacent tissue, and record its relations to the nearest margins.
 - Small lesions should be embedded entirely and larger lesions sampled more extensively.
 - Take blocks from the intervening areas between separate lesions to evaluate whether there is intervening normal tissue or continuity between the lesions. Previous biopsy cavities should be sampled in a similar way.
 - Additional blocks must include random samples of fibrous tissue from each quadrant as well as any macroscopic or radiological abnormalities. The practice of taking random blocks is recommended because it has been demonstrated to provide additional information in approximately a third of mastectomies, particularly in lobular neoplasia.⁵

Neoadjuvant chemotherapy

In patients who have undergone neoadjuvant chemotherapy, accurate pathology reporting is an important contributor to management decisions. As the tumour may have been altered by therapy, particular care should be taken during the macroscopic description of these specimens. A gross estimate of the abnormal areas should be provided, with a meticulous block key to verify the gross impression of the extent of the lesion. Given that gross size underestimates the extent of the residual tumour in approximately half of cases,⁶ care should be taken in selecting blocks.

Core biopsy

If immediate diagnosis is necessary, imprints may be prepared from fresh cores for cytologic examination by gently holding them with forceps and rolling or smearing on a glass slide.

1. Indicate the type of core biopsy (14G, conventional core or the 11G vacuum-assisted biopsy).
2. Record the number of core biopsies received.
3. Measure the approximate maximum length (or aggregate size, if fragmented).
4. If calcium has been confirmed in some of the cores, identify and embed these cores separately from the non-calcium bearing cores.
5. Submit the cores in toto and section at multiple levels.
6. Biological markers may be required (e.g. prior to neoadjuvant therapy).

Tissue banking

Because of the value of fresh tissue for research, there is increasing interest in donating to tissue banks any tissue that is surplus to diagnostic needs. Although this primarily involves the collection of breast cancers, it may also include the banking of benign lesions and normal breast tissue.

Surplus tumour is generally limited to breast cancers larger than 10 mm. Cases in which a clear pre-operative diagnosis has not been established may not be appropriate for tissue banking. Mastectomy specimens with large tumours are best suited for this purpose. Tumours that are managed by conservative surgery may be too small to preserve RNA. In addition, incision into unfixed lumpectomy specimens may compromise further sectioning.

It is the responsibility of the clinical staff to obtain appropriate informed consent for tissue banking. (When designing general consent forms, consider incorporating consent for the use of such surplus tissues.) The pathologist should be notified of the patient's consent by indicating this on the specimen request form.

To be considered for tissue banking, the specimen should be received fresh and preferably on ice in the pathology laboratory within an hour of surgery. The specimen is weighed and measured, orientated, margins are inked and then the specimen is incised. Ideally 10 mm³ of tumour or more is required, together with a separate sample from a distant area of normal breast tissue. The tissue should be cut into small cubes and submitted in appropriately labelled plastic tubes to be snap frozen and collected by tissue bank staff. The remainder of the specimen is then fixed in formalin.

As technology improves it may become possible to extract DNA and RNA from even smaller tissue volumes such as surplus fine-needle aspirate and core biopsy samples, or paraffin blocks.

Examination of lymph nodes for metastasis

Axillary clearance and sampling procedures

All axillary lymph nodes should be dissected from the specimen. Lymph nodes are best identified in the axillary adipose tissue by combined palpation and inspection.

If a sentinel lymph node biopsy has not been performed, the absence of axillary lymph node involvement by metastatic carcinoma cannot reliably be made on examination of fewer than six nodes. Among patients with breast cancer reported as node-negative, examination of fewer than six dissected lymph nodes is a risk factor for poor clinical outcomes, possibly due to understaging.⁷

If the lymph nodes have been divided into three levels by the surgeon, this orientation should be preserved and noted in the block selection key and subsequent report. If a suture is placed at the apex, the examination and block selection should be carried out from one end of the specimen to the other. An indication of whether or not the node closest to the apical suture is involved by metastatic carcinoma should be included in the report. This also applies if the apical node is submitted separately. The pathologist should document any gross extranodal extension of cancer, due to its association with locoregional recurrence.⁸ This should be commented upon, but the soft tissue margins of the axillary clearance specimens are not inked.

Some laboratories find it useful to detach the axillary tissue and fix it in a clearing agent, such as Carnoy's fixative while the breast is fixing in formalin. This renders the fat translucent, making the nodes more readily identifiable.

Small lymph nodes (< 5 mm) should be embedded intact or may be halved. Larger nodes (> 5 mm) require slicing at 2–3 mm intervals to ensure that as much as possible of the lymph node is examined histologically. The number of nodes submitted in each block should be recorded.

In the case of a lymph node with gross involvement by metastatic carcinoma, it is only necessary to block a sample.

Sentinel lymph nodes

Sentinel lymph node specimens carry a very low level of radioactivity. Radiation safety determinations have endorsed examination of nodal specimens in the fresh state.⁹ However, overnight fixation should be considered for the breast tissue specimen that includes the injection site, in order to ensure that staff exposure is as low as reasonably possible, and all procedures should be discussed with the local radiation safety officer.

The gross appearance of the sentinel lymph node should be described, noting particularly if it is blue and if hot by reference to the count provided by the surgeon. The node should be sliced at 2 mm intervals.

A positive result on intraoperative assessment (cytological methods or frozen section) of the sentinel node may negate the need for second surgery, as axillary dissection may be performed immediately. There are two methods of intraoperative assessment for sentinel nodes; cytology and frozen section, both of which provide excellent specificity and acceptable rates of sensitivity. A moderate rate of false negative is inevitable with both techniques.^{10, 11} A potential disadvantage of the frozen section technique is that tissue is discarded during the preparation of the frozen section, and all care should be taken to keep this to a minimum.

Each pathology laboratory, in consultation with the surgical teams, should determine which procedure is most appropriate to be implemented depending on the resources and expertise available in the laboratory. Definitive histological assessment is needed to confirm intraoperative results.

If cytology is required, an imprint is prepared by pressing a glass slide onto the cut surfaces of the sentinel lymph node and staining using a rapid cytologic staining method (e.g. Diff Quik). If cytologic expertise is not available, a slice of the sentinel lymph node may be submitted for frozen section examination.

If intra-operative consultation is not required, the sentinel lymph node may be fixed and subsequently sliced at 2 mm intervals. When the node is grossly positive, one slice is sufficient to document metastasis. Otherwise, all slices of the sentinel lymph node should be submitted in as few blocks as is practical.

A variety of protocols are in use for examining sentinel lymph nodes and the choice partly depends on the laboratory's resources and clinical trial participation. There is strong evidence that the greater the number of sections examined, the greater the chance of detecting metastases. However, the significance of tiny (less than 0.2 mm diameter) metastases (i.e. isolated tumour cells) remains uncertain. The current recommendation is that, if the initial haematoxylin and eosin (H&E) stained section is negative, four levels are cut at 500 micron intervals through the 2 mm slices of the node to ensure detection of metastases of 500 microns and larger. Three of these sections are stained by H&E and one randomly chosen section is stained with an epithelial immunohistochemical stain such as AE1/AE3 or Cam 5.2.

References

1. Owings DV, Hann L, Schnitt SJ. How thoroughly should needle localization breast biopsies be sampled for microscopic examination? A prospective mammographic/pathologic correlative study. *Am J Surg Pathol* 1990; 14: 578–583.
2. Schnitt SJ, Wang HH. Histologic sampling of grossly benign breast biopsies. How much is enough? *Am J Surg Pathol* 1989; 13: 505–512.
3. Guidi AJ, Connolly JL, Harris JR, Schnitt SJ. The relationship between shaved margin and inked margin status in breast excision specimens. *Cancer* 1997; 79: 1568–1573.
4. Abraham SC, Fox K, Fraker D, Solin L, Reynolds C. Sampling of grossly benign breast re-excisions: a multidisciplinary approach to assessing adequacy. *Am J Surg Pathol* 1999; 23: 316–322.
5. Gupta D, Nath M, Layfield LJ. Utility of four-quadrant random sections in mastectomy specimens. *Breast J* 2003; 9: 307–311.
6. Apple SK, Suthar F. How do we measure a residual tumor size in histopathology (the gold standard) after neoadjuvant chemotherapy? *Breast* 2006; 15: 370–376.
7. Blancas I, Garcia-Puche J, Bermejo B, et al. Low number of examined lymph nodes in node-negative breast cancer patients is an adverse prognostic factor. *Ann Oncol* 2006; 17: 1644–1649.
8. Strom EA, Woodward WA, Katz A, et al. Clinical investigation: regional nodal failure patterns in breast cancer patients treated with mastectomy without radiotherapy. *Int J Radiat Oncol Biol Phys* 2005; 63: 1508–1513.
9. Kollias J, Gill PG, Chatterton B et al. sentinel node biopsy in breast cancer: recommendations for surgeons, pathologists, nuclear physicians and radiologists in Australia and New Zealand. *Aust NZ J Surg* 2000; 70: 132–136.
10. Julian T, Krag D, Brown A et al. Preliminary technical results of NSABP B-32, a randomized phase III clinical trial to compare sentinel node resection to conventional axillary dissection in clinically node-negative breast cancer patients. *San Antonio Breast Cancer Symposium*. 2004; Abstract 14.
11. Zavagno G, De Salvo G, Scalco G et al. A randomized clinical trial on sentinel lymph node biopsy versus axillary lymph node dissection in breast cancer. Results of the sentinella/GIVOM trial. *Ann Surg*. 2007;(in press).

5. Microscopic reporting of invasive carcinoma

Synoptic report

The microscopic report of an invasive carcinoma is required to provide information that will help guide treatment and determine the prognosis for the patient. Synoptic reports, which follow a standardised agreed format (Figure 2), offer a systematic method of ensuring that all relevant information is included in a way that is easily interpreted by the clinical team.

The synoptic report can either be used as the definitive pathology report or as a summary provided in addition to a more traditional descriptive report. In either situation, individual laboratories can modify the format of the synoptic report to suit their own laboratory information systems and the requirements of their clinical teams. The synoptic report given in this chapter only includes information for which there is strong evidence of prognostic and/or predictive value. It is available as a download from the National Breast and Ovarian Cancer Centre website(www.nbocc.org.au).

Diagnostic summary

Provide a short summary of the main features of the carcinoma, including size, type, histological grade and lymph node status.

Site

For mastectomy specimens, state the position in the breast using the traditional quadrant notation and/or the clock-face convention and record distance from the nipple. For local excision specimens, state the distance between tumours and distance from margins.

Tumour type

Classification of the tumour type according to the World Health Organization histological classification of tumours of the breast is recommended.¹

Recent molecular studies of breast carcinomas, involving the analysis of a large number of genes, have given rise to a new classification of breast cancer types based on their genetic profile.² One of these cancer types, the “basal-like” carcinoma, has been associated with BRCA1 germline mutations. It is important to identify patients with this cancer type, where possible, because of their increased risk of breast and ovarian cancer.

Invasive carcinoma size and lesion size

In cases in which there is one invasive carcinoma, the largest dimension should be measured from the macroscopic examination of the specimen and, if necessary, confirmed by microscopic examination. In order to verify the macroscopic size, blocks should be selected from the periphery of the observed mass or, in the case of a small carcinoma, a block should be taken to show the maximum dimension of the carcinoma.

Figure 2. Sample synoptic report: invasive carcinoma

Patients name: _____ **Laboratory number:** _____

Diagnostic summary

Specimen type: _____
Location: _____
Tumour type: _____

Lesion size

Invasive tumour size/s (mm): _____
Total extent of lesion (DCIS + invasive carcinoma)* (mm): _____
**If greater than invasive tumour size*

Histological grade

Mitotic rate (per 10 high power fields):	
Mitosis score (1–3):	
Tubular formation score (1–3):	
Nuclear grade (1–3):	
Histological grade (1–3):	

Peritumoural lymphovascular invasion:

absent suspicious
 present present and extensive

Involvement of skin/muscle:

absent present
Please specify: _____

DCIS in specimen

Nuclear grade: low intermediate high
Necrosis: _____ Architecture: _____
Calcification: _____

Resection margins

Invasive carcinoma at resection margin:

No Yes
↳ *Distance from nearest specified margin(s):* _____ ↳ *Orientation of involved margin:* _____
↳ *Extent of involvement (mm):* _____

DCIS at resection margin:

No Yes
↳ *Distance from nearest specified margin(s):* _____ ↳ *Orientation of involved margin:* _____
↳ *Extent of involvement (mm):* _____

LCIS at resection margin:

No Yes

Atypical lobular hyperplasia/lobular carcinoma in situ:

Absent Present
↳ classical pleomorphic

Paget's disease of nipple:

absent present

Non-neoplastic breast changes:

Microcalcification:

absent present
Specify associated pathology: _____

Hormone receptor assay status (if performed)

ER result:	<input type="checkbox"/> Positive <input type="checkbox"/> Negative	
Percentage of nuclei stained:		%
Predominant staining intensity:		
PR result:	<input type="checkbox"/> Positive <input type="checkbox"/> Negative	
Percentage of nuclei stained:		%
Predominant staining intensity:		
HER2 status:		
(Immunohistochemistry score:		
ISH (please specify) result:		

Sentinel lymph nodes

Metastatic carcinoma present in ___ of ___ sentinel lymph nodes examined

	Involved	Size of metastasis
Node 1:	<input type="checkbox"/> Yes <input type="checkbox"/> No	
Node 2:	<input type="checkbox"/> Yes <input type="checkbox"/> No	
Node 3:	<input type="checkbox"/> Yes <input type="checkbox"/> No	
Node 4:	<input type="checkbox"/> Yes <input type="checkbox"/> No	
Node 5:	<input type="checkbox"/> Yes <input type="checkbox"/> No	
Node 6:	<input type="checkbox"/> Yes <input type="checkbox"/> No	

Extent of extranodal carcinoma (mm): _____

Axillary lymph node dissection

Metastatic carcinoma present in ___ of ___ lymph nodes examined

	Number involved	Number identified
Level 1:		
Level 2:		
Level 3:		
Apical:		

Nature of nodal involvement:

focal diffuse

Extent of extranodal carcinoma (mm): _____

Comments

Available for download from www.nbocc.org.au

All measurements should be stated in millimetres. For diffusely invasive carcinomas such as invasive lobular it may be necessary to take several blocks from the periphery of the tumour to establish an accurate size. If the macroscopic and microscopic measurements differ, the microscopic measurement should be recorded. For example, a lesion described macroscopically may, on microscopic examination, prove to be mainly ductal carcinoma in situ (DCIS) with only a small invasive component.

Figure 3 illustrates four commonly encountered situations in which one or more foci of invasive carcinoma are found. Given the absence of any established, evidence-based rules for reporting size, the pathologist must make a judgement in each case. The following approaches are reasonable:

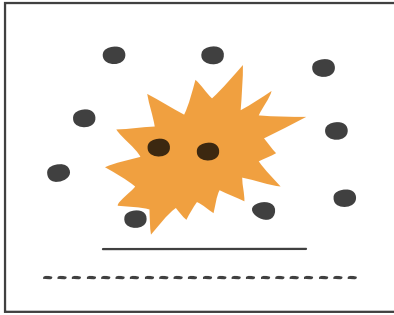
- A single focus of invasive carcinoma associated with DCIS (Figure 3a). The “whole-lesion size” includes any associated DCIS seen beyond the margin of the invasive carcinoma. This measurement often correlates more closely with the lesion size assessed on imaging or clinical examination.
- A lesion predominantly composed of DCIS with multiple microscopic foci of invasive carcinoma (Figure 3b). The whole lesion is measured and the sizes of the invasive carcinoma foci are estimated. The term “microinvasive carcinoma” is used when none of the invasive foci is larger than 1 mm.
- Discrete foci of invasive carcinoma arising in a background of DCIS (Figure 3c). The size of each invasive carcinoma is measured separately. The “whole-lesion size” includes invasive foci and all the associated DCIS.
- More than one focus of invasive carcinoma, each with associated areas of DCIS that are not confluent (Figure 3d). In this situation each is regarded as a separate lesion and measured accordingly. (A separate synoptic report may be necessary for each invasive carcinoma.) The probability of invasive carcinoma arising within a single area of DCIS declines with increasing distance between lesions. A distance of 5 mm or greater is a reasonable arbitrary cut-point for reporting foci as separate lesions.

Small foci of invasive carcinoma separated by dense fibrous tissue are commonly seen after neoadjuvant therapy. It may be necessary to estimate the size of the residual tumour in these cases by measuring the greatest distance between groups of carcinoma cells at the periphery of the involved area.

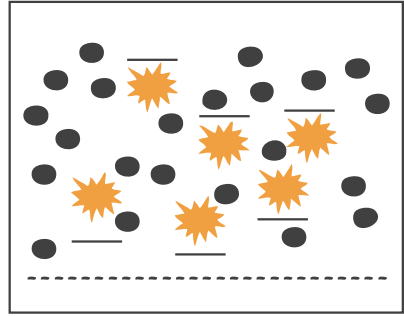
The term “extensive intraductal component” (EIC) has been used to describe those invasive carcinomas in which there is considerable DCIS within the invasive tumour as well as DCIS beyond the margin of the invasive carcinoma. In some studies, EIC tumours showed a higher rate of local recurrence following breast-conserving surgery and radiotherapy, but the significance of this finding is less clear following more recent studies and the shift towards a greater emphasis on marking and examining excision margins of local excision specimens. Therefore, the use of the term EIC is no longer necessary.

The terms “multifocal” and “multicentric” cause confusion because they are poorly defined and used inconsistently, and these should be avoided in pathology reporting.

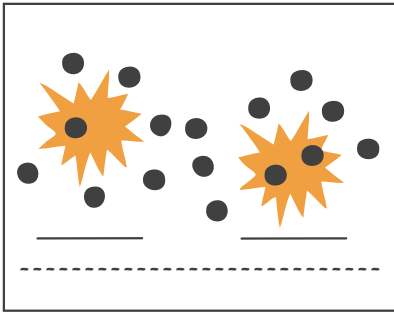
Figure 3. Assessing the size of invasive carcinoma and whole lesion



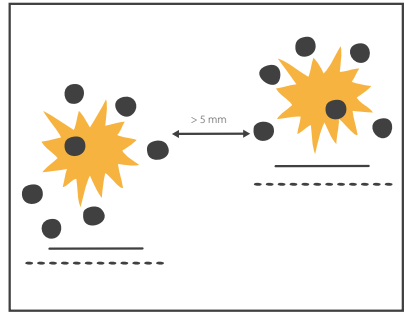
3a. Single focus of invasive carcinoma associated with DCIS



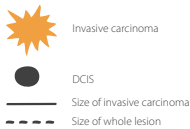
3b. Predominantly DCIS but with multiple, separate, microscopic foci of invasive carcinoma. These often represent foci of microinvasive carcinoma (see text).



3c. More than one invasive carcinoma but arising in a single area of DCIS



3d. More than one invasive carcinoma but arising in separate (non-confluent) areas of DCIS



Histological grade of invasive carcinoma

Invasive carcinomas of all types, including invasive lobular carcinoma, should be graded using the Elston and Ellis modification of the Bloom and Richardson grading system.³ If the carcinoma is too small to be graded then the statement “not assessable” (and the reason) should be inserted in the synoptic report.

Mitotic frequency score

The mitotic frequency score is calculated from the number of mitoses per 10 high-power fields. The count is performed using a 40 x objective at the periphery of the invasive carcinoma and from the area in which most mitoses are seen following a low-power scan of the tumour. It is essential to know the field diameter of the microscope, so that the mitosis score (scale of 1–3) can be calculated from both the field diameter and mitosis count using Figure 4 and Table 1.

Nuclear score

Nuclear score is assessed by reference to normal duct epithelial nuclei using 40 x objective:

- Score 1: Size equivalent to 1.5–2 red blood cell diameters or normal duct epithelial nuclei
Diffuse chromatin
Inconspicuous nucleoli
- Score 2: Size equivalent to 2–2.5 red blood cell diameters
Coarse chromatin
Infrequent nucleoli and mitoses
- Score 3: Size > 2.5 red blood cell diameters
Pleomorphic vesicular nuclei
One or more prominent nucleoli
Frequent mitotic figures commonly present

Tubular formation score

Tubular differentiation is assessed from the overall appearance of the invasive carcinoma scanned at low power and taking into account any acinar, ductal or tubular structures. It is scored according to the percentage of tubular differentiation seen in the carcinoma:

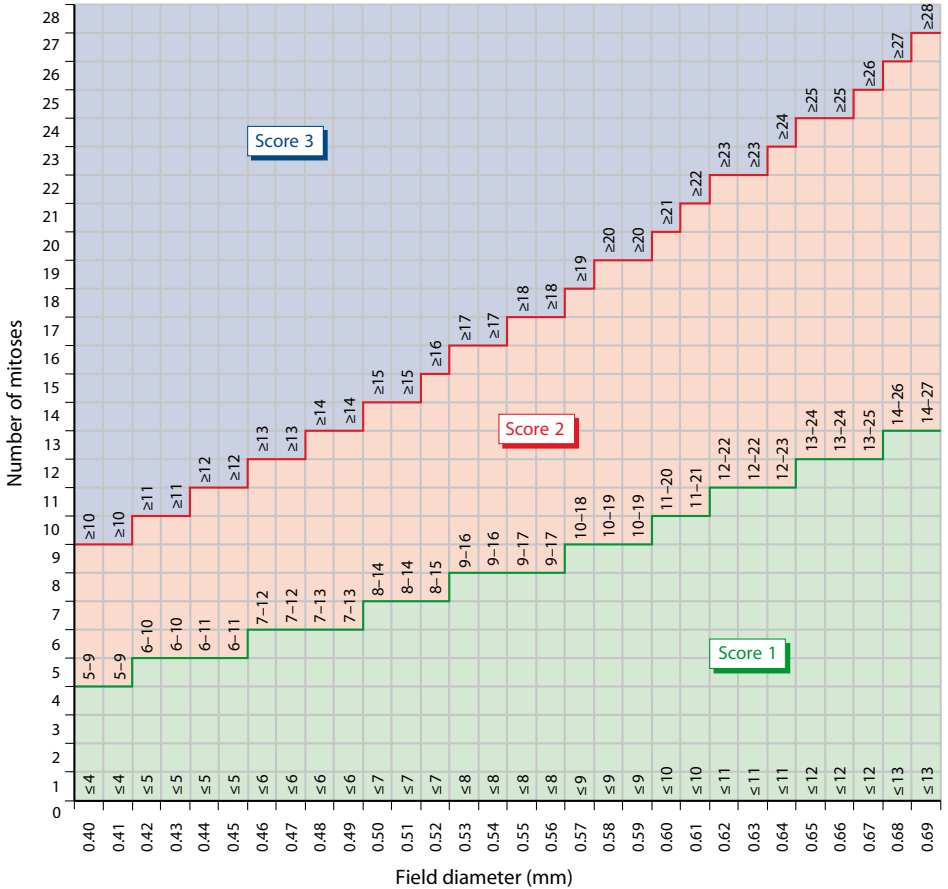
- Score 1 > 75% of invasive carcinoma forming tubular or glandular structures
- Score 2 10–75% of invasive carcinoma forming tubular or glandular structures
- Score 3 < 10% of invasive carcinoma forming tubular or glandular structures

Histological grade

The histological grade is calculated by adding the three scores (mitosis score, nuclear score and tubular differentiation score):

Grade 1	Total score of 3–5
Grade 2	Total score of 6 or 7
Grade 3	Total score of 8 or 9

Figure 4. Calibration of microscope field diameter against mitotic frequency⁴



© NHS Breast Screening Programme. Reproduced with permission

The chart assists calibration of microscope field diameter with mitotic frequency count, showing cut-points for grading (See Table 1)

Table 1. Mitotic counts by field diameter⁴

Field diameter (mm)	Mitotic frequency score		
	1	2	3
0.40	≤4	5–9	≥10
0.41	≤4	5–9	≥10
0.42	≤5	6–10	≥11
0.43	≤5	6–10	≥11
0.44	≤5	6–11	≥12
0.45	≤5	6–11	≥12
0.46	≤6	7–12	≥13
0.47	≤6	7–12	≥13
0.48	≤6	7–13	≥14
0.49	≤6	7–13	≥14
0.50	≤7	8–15	≥15
0.51	≤7	8–15	≥15
0.52	≤7	8–15	≥16
0.53	≤8	9–16	≥17
0.54	≤8	9–16	≥17
0.55	≤8	9–17	≥18
0.56	≤8	9–17	≥18
0.57	≤9	10–18	≥19
0.58	≤9	10–19	≥20
0.59	≤9	10–19	≥20
0.60	≤10	11–20	≥21
0.61	≤10	11–21	≥22
0.62	≤11	12–22	≥23
0.63	≤11	12–22	≥23
0.64	≤11	12–23	≥24
0.65	≤12	13–24	≥25
0.66	≤12	13–24	≥25
0.67	≤12	13–25	≥26
0.68	≤13	14–26	≥27
0.69	≤13	14–27	≥28

Adapted with permission from NHS Breast Screening Programme

Lymphovascular invasion

It is very difficult to distinguish between lymphatics and veins, therefore the term “lymphovascular” is used to cover both possibilities. The most reliable method of assessing whether lymphovascular invasion is present is to examine peritumoural tissue. However, immunostaining may be helpful in individual cases to distinguish true lymphovascular invasion from an artefactual cleft or fat space. Dermal lymphatic invasion when identified should be specified in the report because of its association with inflammatory breast carcinoma.

Lymphovascular invasion should be reported using a descriptor from the following options: absent; suspicious; present; present and extensive.

DCIS in specimen

Nuclear grade is assessed in the same way as for invasive carcinoma, with reference to normal breast epithelial cells (see also **Chapter 6. Microscopic reporting of ductal carcinoma in situ.**)

Resection margins

The distances from the nearest resection margins should initially be assessed on macroscopic examination of the specimen.

For orientated specimens, these measurements should be given in millimetres from the named circumferential margins and including the superficial (subcutaneous adipose tissue) and deep (pectoralis fascia) margins. After painting the margins with coloured inks, the measurements should be confirmed microscopically and blocks should be taken accordingly. This is particularly important with diffusely invasive tumours such as invasive lobular carcinoma. The status of the resection margins for DCIS in association with invasive carcinoma can only be assessed microscopically. A specimen is reported as having a “positive margin” if there is ink on carcinoma cells (DCIS or invasive). For positive margins, the extent of margin involvement has both prognostic and management implications.

Atypical lobular hyperplasia/lobular carcinoma in situ

Atypical lobular hyperplasia (ALH) and lobular carcinoma in situ (LCIS) are documented as being “present” or “absent”. If present, state whether classical or variant type (e.g. pleomorphic, signet ring). Recording the presence of LCIS at margins is recommended, although its clinical significance is uncertain.

There is a trend towards reporting the presence of either ALH or LCIS as “lobular neoplasia”, while some pathology laboratories continue to distinguish routinely between ALH or LCIS. Current World Health Organization classification incorporates the term lobular neoplasia in parallel with the traditional ALH/LCIS terminology (see also **Appendix–Lobular neoplasia**).

Paget’s disease of the nipple

The presence of Paget’s disease of the nipple should be reported, as it may have implications for clinical management and prognosis.

Microcalcification

The presence or absence of microcalcification, and the lesions in which it is seen, should be documented to enable accurate correlation with the pre-operative imaging findings. This is particularly important when the surgery was performed to sample/remove the microcalcifications.

Note: calcium oxalate is only detectable using polarised light.

Benign and proliferative changes

Significant pathology features, such as the following, should be documented if observed:

- columnar cell changes
- intraductal papilloma
- radial scars
- atypical ductal hyperplasia (ADH).

Oestrogen receptor, progesterone receptor and HER2 assays

See **Chapter 7. Hormone receptor assays and other prognostic and predictive factors.**

References

1. Tavasoli FA, Devilee P (Eds). World Health Organization Classification of Tumours. Pathology and genetics of tumours of the breast and female genital organs. Lyon: IARC Press, 2003.
2. Sorlie T, Perou CM, Tibshirini R, et al., Gene expression patterns of breast carcinomas distinguish tumour subclasses with clinical implications. *Proc Natl Acad Sci USA* 2001; 98: 10869–10864.
3. Elston CW, Ellis IO. Pathological prognostic factors in breast cancer. I. The value of histological grade in breast cancer: experience from a large study with long-term follow-up. *Histopathology* 1991; 19: 403–410.
4. Guidelines Working Group of the National Coordinating Committee for Breast Pathology, National Health Service Breast Screening Programme. Pathology reporting of breast disease. A Joint Document Incorporating the Third Edition of the NHS Breast Screening Programme's Guidelines for Pathology Reporting in Breast Cancer Screening and the Second Edition of The Royal College of Pathologists' Minimum Dataset for Breast Cancer Histopathology. NHSBSP Publication No 58. Sheffield, UK: NHS Cancer Screening Programmes and The Royal College of Pathologists, 2005.

6. Microscopic reporting of ductal carcinoma in situ

Ductal carcinoma in situ (DCIS) has various histological forms with differing growth patterns, nuclear morphology, tendency to necrosis and natural history.¹ Although there is currently no consensus classification of DCIS, the most frequently used classification systems assess similar factors, all of which should be included in the report to enable pathology to be correlated with radiological findings and to provide important prognostic information.

The following characteristics should be recorded for each case of pure DCIS:

- Maximal size
- Distance to nearest margins
- Nuclear grade
- Presence or absence of necrosis
- Architecture
- Presence or absence of calcification.

Size

The pathologist should record the maximum dimension of the entire lesion using measurement on the slide and reference to the gross specimen and/or imaging findings as necessary. Ideally, radiographs accompanied by a radiological report should be available to the pathologist at the time of block selection.

The measurement should include any intralobular extension of DCIS. Although DCIS is a contiguous disease, specimen slicing may result in the appearance of uninvolved ducts between involved ducts. In this case, the longest distance between involved ducts should be recorded, including any intervening normal tissue.

Margins

The distance from each margin should be stated in millimetres when less than 10 mm, and otherwise stated as “> 10 mm”. If DCIS is present at the margin, this should be reported, specifying the margin involved and the extent of margin involvement in millimetres.

The phrase “excision is complete” is not recommended for use in reporting, because clear margins do not necessarily mean completeness of excision.

Nuclear grade

Various studies have established nuclear grade as a predictive factor in breast-conserving management of DCIS, although the grading schemes utilised were diverse. In addition, there is significant correlation between DCIS grade and the grade of any corresponding invasive component, if present, regardless of the grading system used.²⁻⁴ Nuclear grade should be reported as low, intermediate or high, using the Elston and Ellis modification of the Bloom and Richardson system for grading invasive carcinoma, according to the following definitions:⁵⁻⁷

Low-grade nuclei (Grade 1):	Size equivalent to 1.5–2 red blood cell diameters or normal duct epithelial nuclei Diffuse chromatin Inconspicuous nucleoli
Intermediate-grade nuclei (Grade 2):	Size equivalent to 2–2.5 red blood cell diameters Coarse chromatin Infrequent nucleoli and mitoses
High-grade nuclei (Grade 3):	Size > 2.5 red blood cell diameters Pleomorphic vesicular nuclei One or more prominent nucleoli Frequent mitotic figures commonly present

If heterogeneity is observed, this should be noted in the report, and the grade reported as the highest grade to which the features correspond.

These grades have also been associated with a range of biological characteristics. Typically, high nuclear grade lesions show an absence of oestrogen and progesterone receptor expression, aneuploidy, a high proliferative index, membrane reactivity for HER2, p53 nuclear expression and abnormal bcl2 expression. Low-nuclear-grade lesions show the converse, and intermediate grade DCIS exhibits mixed patterns of biological marker expression.

Necrosis

Necrosis is defined as the presence of ghost cells and karyorrhectic debris.⁶ Necrosis should be recorded as:

1. Not present or minimal (only isolated apoptotic cells)
2. Present (state whether comedo type or non-comedo type)

Comedocarcinoma is defined as the presence of central duct necrosis and grade 3 nuclei. It is frequently associated with coarse casting microcalcifications.

Van Nuys Prognostic Index

The Van Nuys Prognostic Index (VNPI) incorporates margin status, tumour size, and DCIS group according to the system of prognostic classification of DCIS proposed by Silverstein *et al.*, which is based on the highest nuclear grade present and the presence or absence of necrosis as follows:⁸

- Group 1: nuclear grade 1 or 2 and no necrosis
- Group 2: nuclear grade 1 or 2 and necrosis
- Group 3: nuclear grade 3 with or without necrosis.

Follow-up data have demonstrated a correlation between VNPI and risk of recurrence after breast-conserving surgery.⁸ This index is not in general use, but may be requested by some clinicians.

Architecture

The report should include a description of the architecture. The dominant pattern should be noted, because many tumours show more than one type. Most DCIS falls within the categories of solid, cribriform, micropapillary, apocrine or papillary.

Microcalcification

The primary purpose of recording the presence of histological calcification is to improve understanding of the relationship between radiological and pathological findings. In certain cases, more detailed descriptions of the size and extent of microcalcifications may be needed to assist in confirming excision of the lesion. This may require close consultation with the radiologist and careful histological study, in conjunction with specimen radiography. Microcalcifications should be recorded as present (specify whether associated with necrosis) or absent.

Synoptic report

The synoptic report recommended for DCIS alone is generally similar to that of invasive carcinoma with DCIS (Figure 5).

References

1. Fisher ER, Dignam J, Tan-Chiu E, et al. Pathologic findings from the National Surgical Adjuvant Breast Project (NSABP) eight-year update of Protocol B-17: intraductal carcinoma. *Cancer* 1999; 86: 429–438.
2. Ringberg A, Palmer B, Linell F, et al. Bilateral and multifocal breast carcinoma. A clinical and autopsy study with special emphasis on ductal carcinoma in situ. *Eur J Surg Oncol* 1991; 17: 20–29.
3. Simpson T, Thirlby RC, Dail DH. Surgical treatment of ductal carcinoma in situ of the breast. 10- to 20- year follow-up. *Arch Surg* 1992; 127: 468–472.
4. Boyages J, Recht A, Connolly J, et al. E. Early breast cancer: predictors of breast recurrence for patients treated with conservative surgery and radiation therapy. *Radiother Oncol* 1990; 19: 29–41.
5. Elston CW, Ellis IO. Pathological prognostic factors in breast cancer. I. The value of histological grade in breast cancer: experience from a large study with long-term follow-up. *Histopathology* 1991; 19: 403–410.
6. The Consensus Conference Committee. Consensus Conference on the classification of ductal carcinoma in situ. *Cancer* 1997; 80: 1798–1802.
7. Silverstein MJ, Poller DN, Waisman JR, et al. Prognostic classification of breast ductal carcinoma-in-situ. *Lancet* 1995; 345: 1154–1157.
8. Silverstein MJ, Lagios MD, Craig PH, et al. A prognostic index for ductal carcinoma in situ of the breast. *Cancer* 1996; 77: 2267–2274.

Figure 5. Sample synoptic report: ductal carcinoma in situ

Patients' name:	Laboratory number:
------------------------	---------------------------

Specimen:
Method of localisation:
Location:
Size:
Resection margins:
Nuclear grade: low intermediate high
Necrosis:
 Absent/minimal Present
 ↳ comedo-type non-comedo type
Architecture:

Calcification:
 Absent Present
 ↳ *Associated with necrosis* Yes No

Hormone receptor assay status (if performed)

ER		PR	
Percentage of nuclei stained:	%	Percentage of nuclei stained:	%
Predominant staining intensity:		Predominant staining intensity:	
Non-neoplastic breast changes: <div style="background-color: #cccccc; height: 100px; width: 100%;"></div>			

7. Hormone receptor assays and other prognostic and predictive factors

This field, particularly HER2 testing, is advancing rapidly and information about available tests and recommended protocols may change. Regularly updated information will be available on the National Breast and Ovarian Cancer Centre website (www.nbcc.org.au).

Hormone receptor assays

Immunohistochemical assays of oestrogen receptor (ER) and progesterone receptor (PR) are now routinely performed on invasive breast carcinoma specimens. Both should be reported for all cases of invasive breast carcinoma because they provide independent prognostic information and predict response to hormonal therapy.^{1–3} In ductal carcinoma in situ (DCIS), hormone receptor status may be a predictor of response to hormonal therapy, but further clinical trials are needed to clarify this issue.⁴ Many clinicians now expect hormone receptor status to be evaluated in pure DCIS lesions.

Hormone receptor assays can be performed on paraffin-embedded biopsy material (including core biopsies and excised tissue), cytological smears or cell-block preparations.⁵ For an overview of current issues and controversies concerning hormone receptor assays, refer to the recent reviews and editorials listed in the references.^{3,6–9}

Technical considerations

Tissue should be fixed in formalin as soon as possible after the specimen is taken because receptor antigens may not be preserved if there is a delay in fixation, especially for small biopsies. Fixation may be enhanced by placing a separate thin slice of the tumour in fixative.

Fixation for 24 hours will achieve optimal results for both small samples (e.g. core biopsies) and larger samples (e.g. excision biopsy), because formalin fixation is a time-dependent chemical reaction which proceeds at a similar rate in both cases. Short fixation times (e.g. < 6–8 hours) are likely to compromise hormone receptor assay results.¹⁰ Fixation in hot formalin or fixatives other than 10% neutral buffered formalin may also affect hormone receptor staining.

Immunoreactivity may also be impaired by prolonged formalin fixation (possibly only extreme fixation times) but this risk is rarely relevant, given clinical imperatives for rapid reporting.^{10,11}

Current published evidence is inconsistent as to which type of specimen yields the most accurate results for hormone receptor assays. Some studies favour excision biopsies,^{10,12} while others suggest that core biopsies might provide more reliable hormone receptor estimations than excision biopsies or mastectomies.¹³ Optimal specimen handling is probably the key factor to ensure accurate assays, regardless of specimen type.

Antigen retrieval methods such as microwaving or heating tissue are usually necessary to optimise results.^{3,14} A number of commercially available antibodies are in routine use.³ Both external and internal positive and negative controls should be used. When selecting test blocks,

non-neoplastic ductal tissue should be included to provide an internal positive control that has undergone similar fixation to the carcinoma. Some authors recommend selecting positive controls with both low and high hormone receptor levels, in order to avoid false negative results.⁶

Reporting hormone receptor assay results

Only nuclear staining indicates a positive result. Cytoplasmic staining does not correlate with tumour response to endocrine therapy or biochemical assay results.

The following data should be included in the report as a minimum (Table 2):

- an estimate of the percentage of nuclei stained
- the predominant intensity of staining (low, intermediate or high)
- a conclusion as to whether the assay is positive or negative (see discussion below).

Suggested criteria for a positive assay result:

≥1% nuclei staining at any intensity (low, intermediate or high)

Table 2. Sample report for hormone receptor assay

Oestrogen receptor

Percentage of nuclei stained:

Predominant intensity of staining:

ER result: Positive Negative

Progesterone receptor

Percentage of nuclei stained:

Predominant intensity of staining:

PR result: Positive Negative

The issue of whether an immunohistochemical 'score' provides additional useful clinical information remains controversial and there is no consensus as to the lower cut-point for a positive assay. Some investigators have demonstrated a bimodal (negative versus unequivocally positive) distribution of ER receptor results using current sensitive immunohistochemical methods.^{7,15} However, there is some evidence that quantitative immunohistochemical scores may reflect preanalytic factors and assay sensitivity, rather than true ER protein levels.⁹ Other studies suggest that even a very small number of positive cells is associated with a response to hormonal treatment and have shown a correlation between score and the degree of response to hormonal therapy.^{8,9,16}

Although 1% of positive nuclei has been suggested as the cut-point for a positive assay,³ this may exclude patients who might benefit from hormonal therapy. A 2001 consensus panel of the US National Institutes of Health (NIH) suggested that *any* ER staining in breast cancers is sufficient to consider a tumour ER-positive, and the patient a suitable candidate for endocrine therapy.¹⁷ Therefore, NIH recommends that the pathologist reports the percentage of positive cells and the intensity of staining, to enable clinicians to make a considered judgement, particularly where the results are equivocal. In the absence of consensus, a pragmatic approach is to regard 1% or greater stained nuclei as positive, as suggested above.

The finding of only small numbers of cells with weak positive staining should prompt the pathologist to repeat the assay, with close attention to optimising antigen retrieval, or to use other blocks or specimens from the patient (e.g. core biopsies).

No standardised method for evaluating ER status in DCIS has been validated. A system similar to that used in invasive cancer is recommended, to provide clinicians with information that is relevant to management decisions and clinical trial selection.

Hormone receptor assay results are generally available concurrent with, or within 1–2 days of, the histopathology or cytology report. An integrated synoptic report, including ER and PR, is helpful to ensure that this information reaches the clinical team. The pathology report of breast cancers should include a statement that receptor status is being assessed (including the name of the person responsible for the assays) to enable the clinician responsible to follow up. A copy of hormone receptor assay results should be sent to the surgeon and other managing clinicians and (where performed by an external pathology service) to the originating pathology department.

Quality control

Quality assurance for hormone receptor estimations is the subject of considerable literature and some controversy. Concerns about significant inter-laboratory variation and suboptimal sensitivity in many laboratories have arisen from national surveys conducted in the UK, Europe and the USA.^{6,14,18–20}

Australian laboratories reporting on the histopathology of breast cancers are required to participate in quality assurance programs both for routine diagnosis and for immunohistochemistry evaluation. The Royal College of Pathologists of Australasia (RCPA) Quality Assurance Program includes a specific Breast Marker Module and an audit of ER, PR and HER2 results.

HER2 assays

Testing for HER2 (c-erbB-2, HER2/neu) status is now recommended for all newly diagnosed early invasive breast cancers, and is also likely to be requested in the setting of recurrent or metastatic disease.²¹ HER2 status predicts the response to specific antibody therapy, and several other systemic therapies, as well as being a general prognostic marker.²¹ Currently available techniques for routinely evaluating HER2 status include immunohistochemistry for detecting protein overexpression and *in situ* hybridisation for detecting gene amplification.

In situ hybridisation assays for detecting gene amplification include:

- brightfield in situ hybridisation, e.g. chromogenic in situ hybridisation (CISH, Invitrogen) and automated silver in situ hybridisation (SISH, Ventana)
- fluorescence in situ hybridisation (FISH; Vysis, Ventana).

Under the Australian Pharmaceutical Benefits Scheme (PBS):

- Patients with early breast cancer are eligible for immunotherapy with trastuzumab (Herceptin, Roche) only if HER2 gene amplification has been demonstrated by in situ hybridisation.
- Patients with metastatic disease are eligible for trastuzumab therapy if a 3+ positive result has been demonstrated by immunohistochemistry or HER2 gene amplification has been demonstrated by in situ hybridisation.

Accurate assays are important because antibody therapy is costly and is associated with cardiac toxicity in a small but significant number of patients.²¹

The percentage of breast carcinomas that are HER2 positive varies depending on the method used in the assay and the patients selected for testing. Overall, 15–20% of invasive carcinomas will show HER2 protein overexpression and/or gene amplification.^{21,22}

Of the tests available in Australia to assess HER2 in the pathology laboratory, immunohistochemistry and CISH are the two most used. As more laboratories become certified for CISH testing, the CISH assay is replacing the FISH assay. Newer in situ hybridisation assays using brightfield microscopy (e.g. SISH) are also now available.

All the available tests have advantages and disadvantages with regard to accuracy, reproducibility, ease of application and cost. Laboratories can be certified for in situ hybridisation testing through an RCPA-endorsed training, certification and quality assurance programme conducted by Invitrogen, Ventana and Roche. Roche will provide financial support for testing for a limited period. A similar model is likely to be implemented for other in situ hybridisation assays as these become available.

Within the pathology community there has been considerable debate about how testing for HER2 status should be implemented. Clinical trials that validated HER2-positive status as a predictor of response to trastuzumab were based mainly on immunohistochemistry with central review, and sometimes by centralised FISH testing.²¹ However, several studies have documented significant rates of false-positive and false-negative reporting of HER2 immunohistochemistry when centralised re-testing results have been compared with peripheral laboratory results.²¹

To date, the majority of Australian experience has been with immunohistochemistry in pathology laboratories, and adjunctive FISH testing conducted in specialist laboratories for equivocal cases or to help in the quality control of immunohistochemistry results. A review of data from laboratories participating in the RCPA quality assurance program for immunohistochemistry revealed that HER2 immunohistochemistry results for breast cancers show an overall positive (3+) rate of 17.1% for all participating laboratories, consistent with international rates.^{21,22} More recently, CISH testing has been used to supplement

immunohistochemistry. CISH or other forms of brightfield in situ hybridisation are likely to become the initial tests of choice.

Advantages of brightfield in situ hybridisation (CISH, SISH) include the following:

- Less expensive than FISH
- Does not require a fluorescence microscope
- Provides durable staining; samples can be stored without signal loss²³
- More easily interpreted by a histopathologist with basic training in the technique²⁴
- Enables screening of whole sections at low power to confirm diagnoses and facilitate selection of areas of tissue to evaluate²⁴
- Potential application in all routine histopathology laboratories.

Satisfactory inter-laboratory agreement for CISH results and satisfactory correlation with FISH results have been demonstrated in Australian and international studies.^{24,25} Debate has focused on whether testing should be restricted to laboratories with considerable ongoing experience in applying the techniques.^{21,22} The Roche system of certification of laboratories for HER2 CISH and SISH testing has been accepted by the RCPA and by the Commonwealth Government, and should provide widespread, accurate and timely access to HER2 in situ hybridisation testing.

As with all tests, inter-laboratory variation does not necessarily imply poor quality of testing, and 100% sensitivity and predictive value are inherently impossible. There is no true 'gold standard' for HER2 testing, and test accuracy is limited even in reference laboratories.

A standardised approach to HER2 testing

The field of HER2 assays is rapidly developing and subject to change. Recently updated consensus guidelines for HER2 testing in breast cancer developed by the American Society of Clinical Oncologists and the College of American Pathologists provide a comprehensive discussion of preanalytic, analytic and postanalytic sources of variation in HER2 testing results by immunohistochemistry and FISH.²¹ Although CISH testing is not specifically reviewed, much of the discussion can be extrapolated to brightfield in situ hybridisation.

As for any other tissue-based testing, in situ hybridisation results are likely to be influenced by handling factors including time to fixation, duration of fixation, type of fixative and methods of tissue processing. These variables are less likely to lead to a false positive or false negative result than is the case with immunohistochemistry, but they can lead to a weak or non-diagnostic signal. There has been little formal study of these variables for in situ hybridisation, but most studies have been based on tissue fixed in neutral buffered formalin.^{23,26} Carnoy's fixative has been found to compromise in situ hybridisation processing, as has decalcification in strong acids. An Australian inter-observer study of CISH testing reported low inter-observer variability for routinely processed paraffin blocks from multiple laboratories, with good correlation between CISH, FISH and immunohistochemistry.²³ International studies have shown similar results.²⁵ However, meticulous attention to the optimisation of all aspects of the CISH process is required to achieve consistent results, even after comprehensive training, in the experience of currently certified Australian laboratories.

It is recommended that laboratories adopting in situ hybridisation in cases of early breast cancer continue to conduct immunohistochemistry concurrently, to enable cross-validation of results, particularly during the early phase of implementation. Immunohistochemistry is also more likely to detect a case with clonal HER2 amplification than in situ hybridisation.

Technical considerations

HER2 assays should be performed on a formalin-fixed, paraffin embedded block which is well fixed and devoid of areas of necrosis, surgical artefact and poor preservation. A thinly sliced sample, fixed as soon as possible after surgery, is likely to provide best results. Fixation in an adequate volume of formalin for a minimum of 6–8 hours (and preferably 24 hours) is recommended.

When reporting on in situ hybridisation slides, a corresponding haematoxylin and eosin stained slide is needed to identify and localise the invasive carcinoma. Ductal carcinoma in situ should not be scored. Currently, in situ hybridisation should only be performed on core biopsies in special circumstances (e.g. when neoadjuvant therapy is planned), and only when the tissue is well fixed in neutral buffered formalin and lacks serious crush, edge or retraction artefact. In the event that brightfield in situ hybridisation does not provide a definitive result for an early breast cancer case, or if certified in situ hybridisation testing is not available, a sample should be referred to the FISH testing facility at St Vincent's Hospital, Sydney.

Testing algorithms for immunohistochemistry and in situ hybridisation in both early and metastatic breast cancers are shown in Figures 6 and 7. The cut-points recommended for adoption by Australian laboratories are those advocated by the American Society of Clinical Oncology and College of American Pathologists (ASCO/CAP) review by Wolff, *et al.*,²¹ summarised as follows.

For immunohistochemistry (Table 3):

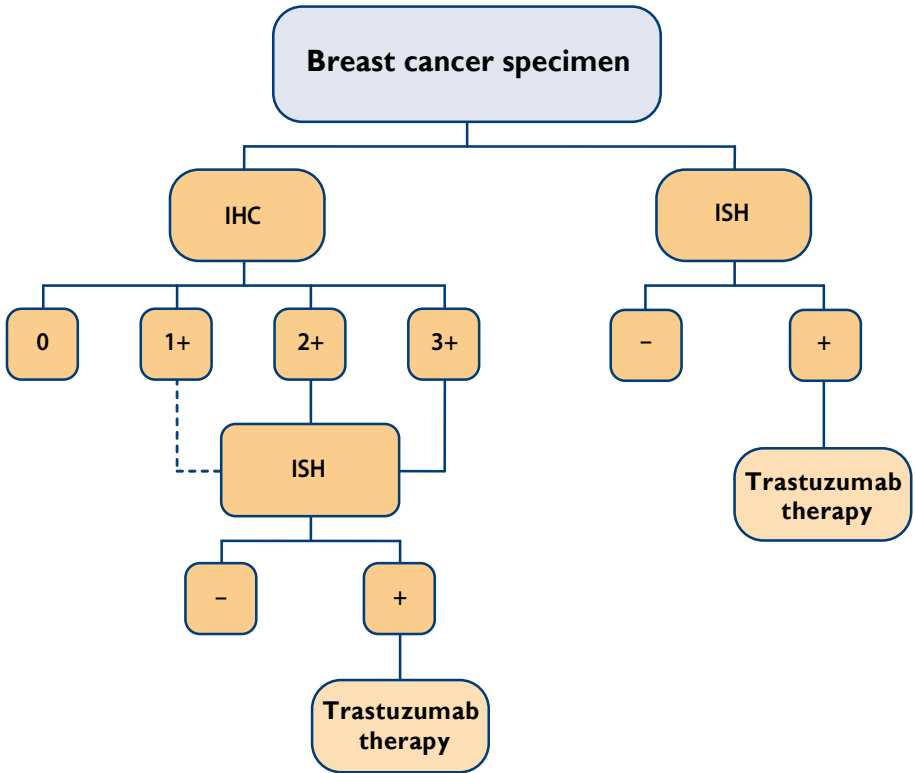
- A positive HER2 result is 3+, uniform, intense membrane staining of > 30% of invasive carcinoma cells.
- A negative result is 0 or 1+ staining.
- An equivocal result is 2+. (In this case, in situ hybridisation testing is required.)

For in situ hybridisation:

- A positive HER2 result is more than 6 copies of the HER2 gene per nucleus or a ratio of HER2 gene signals to chromosome 17 signals of more than 2.2.
- A negative result is less than 4 copies of the HER2 gene per nucleus or a ratio of HER2 gene signals to chromosome 17 signals of less than 1.8.
- An equivocal result is an average of between 4 and 6 HER2 gene copies per nucleus with a single probe or a ratio of HER2 gene signals to chromosome 17 signals in the range of 1.8–2.2. (In this case additional nuclei are counted, the case is retested or immunohistochemistry testing may be performed.)

For full details of the ASCO/CAP recommendations and a comprehensive review see Wolff, *et al.*²¹

Figure 6. Algorithm for HER2 testing for patients with early breast cancer



IHC: immunohistochemistry; ISH: in situ hybridisation

Notes:

Roche will fund in situ hybridisation testing on all breast cancer cases.

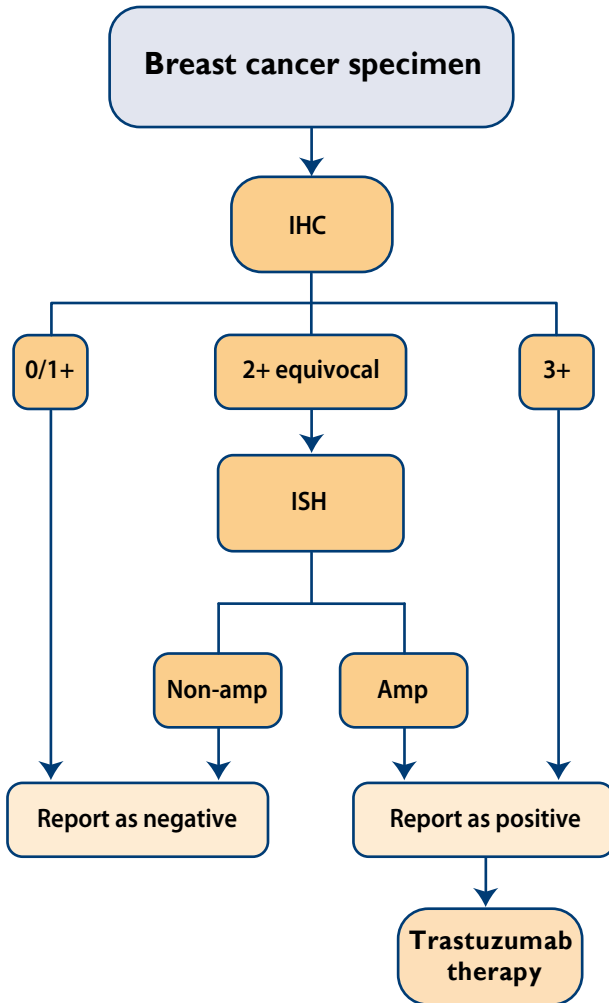
All IHC 2+ and 3+ cases **must** be re-tested by in situ hybridisation; 2+ is an equivocal result requiring additional testing; 3+ is a positive result requiring in situ hybridisation confirmation in order to be able to be treated by trastuzumab according to PBS requirements

IHC 1+ cases should be re-tested by in situ hybridisation if there is any doubt of the validity of the test or if it is considered that there is a possibility that a false negative result has been obtained, e.g. high-grade invasive carcinoma

In the event that in situ hybridisation does not provide a definitive result for an early breast cancer case, the case should be referred to the FISH testing facility at St Vincent’s Hospital, Sydney.

If an immunohistochemistry test is unsatisfactory (e.g. problems with controls or technique), retest by in situ hybridisation.

Figure 7. Algorithm for HER2 testing for patients with metastatic breast cancer



IHC: immunohistochemistry; ISH: in situ hybridisation; Amp: test positive for gene amplification

Notes

Immunohistochemistry 3+ is accepted as an indication for eligibility for trastuzumab treatment without confirmatory in situ hybridisation testing. However, confirmation by in situ hybridisation testing is recommended if there is any doubt about the validity of a 3+ result. Immunohistochemistry 2+ is an equivocal result requiring in situ hybridisation re-testing.

Table 3. Guide to interpretation of HER2 immunohistochemistry test

3+ (HER2 positive)

> 30% of cancer cells show strong, complete membrane staining without cytoplasmic staining and without staining of normal breast tissue (ASCO/CAP: 30% rather than 10%)

2+ (equivocal)

< 10% of cancer cells show strong complete membrane staining (rare) or 10–30% of cancer cells show weak to moderate complete membrane staining or Strong cytoplasmic staining is present, making assessment of membrane staining difficult

0 or 1+ (HER2 negative)

No staining (0) or < 10% of cancer cells show staining (1+)

Other markers

A large number of other prognostic and predictive markers are available for the assessment of invasive breast cancers, predominantly by immunohistochemistry. None of these is currently recommended for routine assay in pathology laboratories, except as part of a research trial or as a defined project in collaboration with clinical units that may be assessing their role.

References

1. Mohsin SK, Weiss H, Havighurst T, et al. Progesterone receptor by immunohistochemistry and clinical outcome in breast cancer: a validation study. *Mod Pathol* 2004; 17: 1545–1554.
2. Osborne CK, Schiff R, Arpino G, Lee AS, Hilsenbeck VG. Endocrine responsiveness: understanding how progesterone receptor can be used to select endocrine therapy. *Breast* 2005; 14: 458–465.
3. Diaz LK, Sneige N. Estrogen receptor analysis for breast cancer: current issues and keys to increasing testing accuracy. *Adv Anat Pathol* 2005; 12: 10–19.
4. Bryant J, Land S, Allred C, et al. DCIS: evidence from randomized trials. *Breast. Suppl* 1: S9, 2003.
5. Sneige N. Utility of cytologic specimens in the evaluation of prognostic and predictive factors of breast cancer: current issues and future directions. *Diagn Cytopathol* 2004; 30: 158–165.
6. Wells CA, Sloane JP, Coleman D, et al. European Working Group for Breast Screening Pathology. Consistency of staining and reporting of oestrogen receptor immunocytochemistry within the European Union—an inter-laboratory study. *Virchows Arch* 2004; 445: 119–128.
7. Nadji M, Gomez-Fernandez C, Ganjei-Azar P, Morales AR. Immunohistochemistry of estrogen and progesterone receptors reconsidered: experience with 5,993 breast cancers. *Am J Clin Pathol* 2005; 123: 21–27.
8. Swanson PE, Schmidt RA. Beneath the surface of the mud, part II: the dichotomization of continuous biologic variables by maximizing immunohistochemical method sensitivity. *Am J Clin Pathol* 2005; 123: 9–12.
9. Schnitt SJ. Estrogen receptor testing of breast cancer in current clinical practice: what's the question? *J Clin Oncol* 2006; 24: 1797–1799.

10. Goldstein NS, Ferkowicz M, Odish E, Mani A, Hastah F. Minimum formalin fixation time for consistent estrogen receptor immunohistochemical staining of invasive breast carcinoma. *Am J Clin Pathol* 2003; 120: 86–92.
11. Arber DA. Effect of prolonged formalin fixation on the immunohistochemical reactivity of breast markers. *Appl Immunohistochem Mol Morphol* 2002; 10: 183–186.
12. Wood B, Junckerstorff R, Sterrett G, Frost F, Harvey J, Robbins P. A comparison of immunohistochemical staining for oestrogen receptor, progesterone receptor, and HER2 in breast core biopsies and subsequent excisions. *Pathology* 2007; 39: 391–395.
13. Mann GB, Fahey VD, Feleppa F, Buchanan MR. Reliance on hormone receptor assays of surgical specimens may compromise outcome in patients with breast cancer. *J Clin Oncol* 2005; 23: 5148–5154.
14. Rhodes A, Jasani B, Balaton AJ, et al. Study of interlaboratory reliability and reproducibility of estrogen and progesterone receptor assays in Europe. Documentation of poor reliability and identification of insufficient microwave antigen retrieval time as a major contributory element of unreliable assays. *Am J Clin Pathol* 2001; 115: 44–58.
15. Collins LC, Botero ML, Schnitt SJ. Bimodal frequency distribution of estrogen receptor immunohistochemical staining results in breast cancer: an analysis of 825 cases. *Am J Clin Pathol* 2005; 123: 16–20.
16. Harvey JM, Clark GM, Osborne CK, Allred DC. Estrogen receptor status by immunohistochemistry is superior to the ligand-binding assay for predicting response to adjuvant endocrine therapy in breast cancer. *J Clin Oncol* 1999; 17: 1474–1481.
17. Eifel P, Axelson JA, Costa J, et al. National Institutes of Health Consensus Development Conference Statement: adjuvant therapy for breast cancer, November 1-3, 2000. *J Natl Cancer Inst* 2001; 93: 979–989.
18. Rhodes A, Jasani B, Balaton AJ, Miller KD. Immunohistochemical demonstration of oestrogen and progesterone receptors: correlation of standards achieved on in house tumours with that achieved on external quality assessment material in over 150 laboratories from 26 countries. *J Clin Pathol* 2000; 53: 292–301.
19. Rhodes A, Jasani B, Barnes DM, Bobrow LG, Miller KD. Reliability of immunohistochemical demonstration of oestrogen receptors in routine practice: interlaboratory variance in the sensitivity of detection and evaluation of scoring systems. *J Clin Pathol* 2000; 53: 125–130.
20. Layfield LJ, Goldstein N, Perkinson KR, Proia AD. Interlaboratory variation in results from immunohistochemical assessment of estrogen receptor status. *Breast J.* 2003; 9: 257–259.
21. Wolff AC, Hammond ME, Schwartz JN, et al. American Society of Clinical Oncology/College of American Pathologists guideline recommendations for human epidermal growth factor receptor 2 testing in breast cancer. *J Clin Oncol* 2007; 25: 118–145.
22. Francis GD, Dimech MK, Giles L, Hopkins A. Frequency and reliability of oestrogen receptor, progesterone receptor and HER2 in breast carcinoma determined by immunohistochemistry in Australasia: Results of the RCPA Quality Assurance Program. *J Clin Pathol* 2007; 60: 1277–1283.
23. Bilous M, Morey A, Armes J, Cummings M, Francis G. Chromogenic in situ hybridisation testing for HER2 gene amplification in breast cancer produces highly reproducible results concordant with fluorescence in situ hybridisation and immunohistochemistry. *Pathology* 2006; 38: 120–124.
24. Bilous M, Dowsett M, Hanna W, et al. Current perspectives on HER2 testing: a review of national testing guidelines. *Modern Pathology* 2003; 16: 173–182.
25. van de Vijver M, Rueschoff J, Penault-Lorrca F, et al. Chromogenic in situ hybridisation (CISH) compared with FISH and IHC for detection of HER2 gene amplification: an international validation ring study. *Breast Cancer Res Treat* 2003; 82(Suppl 1): Abstr 324.
26. Zhao J, Wu R, Marquez A, Yu Y, Shi Z. Determination of HER2 gene amplification by chromogenic in situ hybridization (CISH) in archival breast carcinoma. *Mod Pathol* 2002; 15: 657–665.

Appendix–Lobular neoplasia

Despite the many decades that have elapsed since lobular carcinoma in situ (LCIS) was described by Foote and Stewart in 1941,¹ problems and confusion surrounding the most appropriate terminology and classification persist. The long-term management of LCIS after diagnosis remains problematic.

Foote and Stewart chose the term LCIS to emphasize the morphologic similarities with the cells of frankly invasive lobular carcinoma (ILC). Lobular carcinoma in situ is analogous to ductal carcinoma in situ (DCIS), in that both are characterised by cells that are morphologically similar to those of invasive cancer and remain contained within a basement membrane. Because LCIS was considered a precursor lesion, mastectomy remained the standard recommended management strategy for many years.

More recently, the term atypical lobular hyperplasia (ALH) has been introduced to describe morphologically similar but less well-developed lesions. An all-encompassing term, “lobular neoplasia”, was introduced by Haagensen *et al.* in 1978² to cover both ALH and LCIS. Current World Health Organization classification incorporates the term lobular neoplasia in parallel with the traditional ALH/LCIS terminology.³

Morphologically, lobular neoplasia is defined as ‘a proliferation of generally small and often loosely cohesive cells originating in the terminal duct–lobular unit, with or without pagetoid involvement of terminal ducts.’³ The most common type (‘classical’ LCIS), is composed of acini filled with a monomorphic population of small, round, polygonal or cuboidal cells, with a thin rim of clear cytoplasm and a high nuclear-to-cytoplasmic ratio.^{1,4} The nuclei are uniform and the chromatin fine and evenly dispersed. A characteristic cytologic feature is the presence of cells containing intracytoplasmic lumina or magenta bodies. Loosely cohesive and regularly spaced cells fill and distend the acini, yet overall lobular architecture is maintained.^{1,4} Glandular lumina are not seen and mitoses, calcification, and necrosis are uncommon. Pagetoid spread, where the neoplastic cells extend along adjacent ducts between intact overlying epithelium and underlying basement membrane, is also frequently seen.

The term ALH⁵ is used when involved terminal duct–lobular unit are not completely distended or when residual lumens are present, while LCIS is used for fully developed lesions. Clearly, the differentiation between ALH and LCIS on these criteria is rather arbitrary, and prone to inter- and intra-observer variability. The term lobular neoplasia replaces these terms and encompasses the whole spectrum of lobular epithelial proliferations, although it has not been widely accepted by pathologists.

The cells contained in classic ALH/LCIS, as described above, are also referred to as type A cells. A well-recognised subtype of LCIS is an architecturally similar lesion containing cells with larger nuclei, some increase in pleomorphism and more abundant cytoplasm. These cells are known as type B cells.⁶

Several subtypes of lobular neoplasia have been described. These include endocrine, amphicrine, apocrine, histiocytoid, rhabdoid, signet ring and pleomorphic variants.^{7–9}

On occasions a regular, evenly spaced monotonous population is seen within both ducts and lobules; in these circumstances it may be difficult to classify the lesion as DCIS or LCIS. If both ducts and lobules contain epithelial proliferation of this type, categorisation as both LCIS and DCIS is recommended at the present time to acknowledge the precursor risk of DCIS and the bilateral cancer risk of LCIS. E-cadherin staining may be helpful in classifying the lesion.

Although, over the last few decades, lobular neoplasia has been thought to be only a risk factor rather than a true precursor lesion, there is increasing evidence from morphological, immunophenotypic and molecular investigation that it is both a risk factor and a true precursor of invasive carcinoma. At present, it is not possible to predict which cases of lobular neoplasia will progress.

The presence of lobular neoplasia (ALH/LCIS) should be recorded in the microscopic report. It is recommended that further categorisation into classic or variant type (e.g. pleomorphic, signet ring) be also documented. The presence of LCIS at margins should be recorded, although this does not necessarily have the same significance as DCIS.

References

1. Foote FW, Stewart FW. Lobular carcinoma in situ. *Am J Pathol* 1941; 491–495.
2. Haagensen CD, Lane N, Lattes R, Bodian C. Lobular neoplasia (so-called lobular carcinoma in situ) of the breast. *Cancer* 1978; 42: 737–769.
3. Tavasoli FA, Devilee P (Eds). *World Health Organization Classification of Tumours. Pathology and genetics of tumours of the breast and female genital organs*. Lyon: IARC Press, 2003.
4. Schnitt SJ, Morrow M. Lobular carcinoma in situ: current concepts and controversies. *Semin Diagn Pathol* 1999; 16: 209–23.
5. Page DL, Dupont WD, Rogers LW, Rados MS. Atypical hyperplastic lesions of the female breast. A long-term follow-up study. *Cancer* 1985; 55: 2698–2708.
6. Simpson PT, Gale T, Fulford LG, Reis-Filho JS, Lakhani SR. The diagnosis and management of pre-invasive breast disease: pathology of atypical lobular hyperplasia and lobular carcinoma in situ. *Breast Cancer Res* 2003; 5: 258–562.
7. Eusebi V, Betts C, Haagensen DE, et al. Apocrine differentiation in lobular carcinoma of the breast: a morphologic, immunologic, and ultrastructural study. *Hum Pathol* 1984; 15: 134–140.
8. Merino MJ, Livolsi VA. Signet ring carcinoma of the female breast: a clinicopathologic analysis of 24 cases. *Cancer* 1981; 48: 1830–1837.
9. Middleton LP, Palacios DM, Bryant BR, et al. Pleomorphic lobular carcinoma: morphology, immunohistochemistry, and molecular analysis. *Am J Surg Pathol* 2000; 24: 1650–1656.









www.nbocc.org.au

© National Breast and Ovarian Cancer Centre 2008
Funded by the Australian Government Department of Health and Ageing

PAT 07/08